



## Evaluation of facial complications of hyaluronic acid fillers

Aret Çerçi Özkan<sup>1</sup>, Burcu Çelet Özden<sup>2</sup>

<sup>1</sup>Department of Emergency Medicine and First Aid, European Vocational High School, Istanbul, Turkey

<sup>2</sup>Department of Medical Sciences, Hasan Kalyoncu University, Gaziantep, Turkey

### ABSTRACT

**Objectives:** This study aims to evaluate facial complications of dermal fillers and to increase the public awareness about serious adverse outcomes of these applications.

**Patients and Methods:** Between January 2015 and June 2019, a total of 12 patients (2 males, 10 females; mean age 41 years; range, 28 to 64 years) who experienced hyaluronic acid (HA) filler-related complications were retrospectively analyzed. Complications were recorded using the hospital records.

**Results:** The mean follow-up was 7 (range, 6 to 9) months. In one patient, livedo reticularis over the nose caused by the filler to the nasolabial fold was seen. In another patient, livedo reticularis over the nose caused by the HA filler for tip augmentation was observed. Both patients were treated with heating and oral acetylsalicylic acid. In another two patients, cellulitic infections were observed. Oral antibiotics and topical antibiotic cream were applied. In two patients, infraorbital edema was seen caused by HA filler application to the nasojugal folds. Hyaluronidase was applied for treatment. In two patients, a granuloma was seen at the right infraorbital region and at the left nasolabial region, respectively. Both of them were treated with hyaluronidase. In one patient, a granuloma and infectious abscess of the upper lip caused by the HA filler application for lip augmentation was observed. For the treatment of the abscess, surgical drainage was used and hyaluronidase was applied for the treatment of the granuloma. In three patients, bruising was observed which was treated with the Arnica cream.

**Conclusion:** Our study results show that fillers are not completely innocent products. We recommend that these materials should be used in experienced hands in accordance with the relevant regulations.

**Keywords:** Clivedo reticularis, complication, filler, granuloma, hyaluronic acid.

Dermal fillers rank second following botulinum toxin injection among the list of the most common non-surgical aesthetic procedures.<sup>[1]</sup> The increasing popularity of filler injections has predictably led to an unfortunate rise in the rate of related complications. However, filler practitioners, many of whom may not necessarily be licensed physicians, seem to be reluctant in admitting and bearing the responsibility of these complications.

Nevertheless, it should be noted that these events may occur even in the hand of the most talented injectors and even when they are familiar to the whole anatomy and they take all necessary precautions.<sup>[2]</sup>

Informing all types of filler-related complications is highly valuable to increase public awareness about the seriousness of such medical applications and to emphasize the importance of opting for the qualified, certified

Received: July 22, 2019 Accepted: September 07, 2019 Published online: November 13, 2019

Correspondence: Aret Çerçi Özkan, MD. Avrupa Meslek Yüksek Okulu Acil Tıp ve İlk Yardım Anabilim Dalı, 34010 Zeytinburnu, İstanbul, Turkey.

e-mail: aretmd@hotmail.com

Doi: <http://dx.doi.org/10.5606/Tr-ENT.2019.29591>

### Citation:

Özkan AÇ, Çelet Özden B. Evaluation of facial complications of hyaluronic acid fillers. Tr-ENT 2019;29(3):134-141.

and, most importantly, authorized applicators. A detailed definition and illustration of related complications may hopefully discourage unauthorized applicators and reduce their ignorance.

In the present study, we aimed to evaluate facial complications of facial dermal fillers and to increase the public awareness about serious adverse outcomes of these applications.

### PATIENTS AND METHODS

Between January 2015 and June 2019, a total of 123 hyaluronic acid (HA) filler applications were performed in the private office of the first author. A written informed consent of each patient was obtained before the filler application. In total, 12 patients (2 males, 10 females; mean age 41 years; range, 28 to 64 years) who experienced HA filler-related complications were retrospectively analyzed. Data were retrieved from the hospital archives.

A written informed consent was obtained from each patient. The study was conducted in accordance with the principles of the Declaration of Helsinki.

### RESULTS

The mean follow-up was 7 (range, 6 to 9) months. Complications included vascular complications, acute cellulitic infections, infraorbital edema, granuloma, abscess, and bruising. Type of the HA filler, related complications, and management strategies are summarized in Table 1.

The most serious complication after HA filler application was vascular complication in two patients. In one female patient, livedo reticularis (i.e., macular, violaceous mottling skin discoloration) localized over the right ala nasi probably due to venous obstruction was seen after HA filler application to the right nasolabial fold with a 30-gauge needle (Figure 1). In another female patient having three previous rhinoplasties, one to three-sec blanching at the columella and livedo reticularis localized over the nasal tip and right lateral nasal dorsum were observed after HA filler application for tip augmentation with a 30-gauge needle (Figure 2). In both patients, capillary refill time was found

to be normal (two sec) and these two patients were treated conservatively with the application of warm pads and low-dose oral acetylsalicylic acid. Hyaluronidase was kept ready to be used in case of worsening of the symptoms or the involvement of ischemic findings, but was not needed during the course of these unpleasant events. Livedo in the right nasal ala in the first patient continued for three weeks with gradual fading. Livedo of the nasal tip in the second patient gradually resolved 24 h after HA filler application. Both of these patients never complained about any pain, and capillary refill time was always normal (two sec) during the course of the events.

In two patients, one male and one female, acute cellulitic infections were observed. In the female patient, cellulitis was observed over the right nasolabial fold, while in the male case, cellulitis was observed over the left cheek and left the nasolabial region three to five days after the nasolabial application of the HA filler (Figure 3). Empiric use of oral antibiotics (amoxicillin-clavulanate, 1,000 mg, bid) and topical application of antibiotic cream (fusidic acid, bid) with non-steroidal, anti-inflammatory medication (naproxen sodium, 550 mg, bid) were applied to both patients. Acute cellulitic infections in these patients resolved totally within one week of treatment. No systemic signs of infection were seen or none of the patients needed further treatment modalities.

In two female patients, unilateral, prolonged infraorbital edema was encountered after the application of HA to the nasojugal folds. Initially, vigorous massaging was advised to both, but one month later, hyaluronidase (20 to 30 U) was applied to eliminate edema caused by the filler.

In two patients, one female and one male, a granuloma (culture-negative inflammatory nodule) formation was seen at the right infraorbital region and at the left nasolabial region, respectively. Both of them were treated with hyaluronidase (20 to 30 U) with empiric antibiotics (amoxicillin-clavulanate).

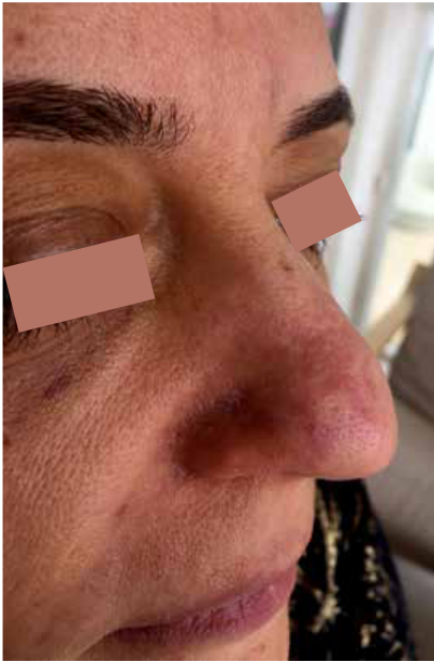In one female patient, a granuloma at the right side of the upper lip caused by a previous unknown filler one year ago and subacute

**Table 1.** Type of the hyaluronic acid filler, related complications, and management strategies

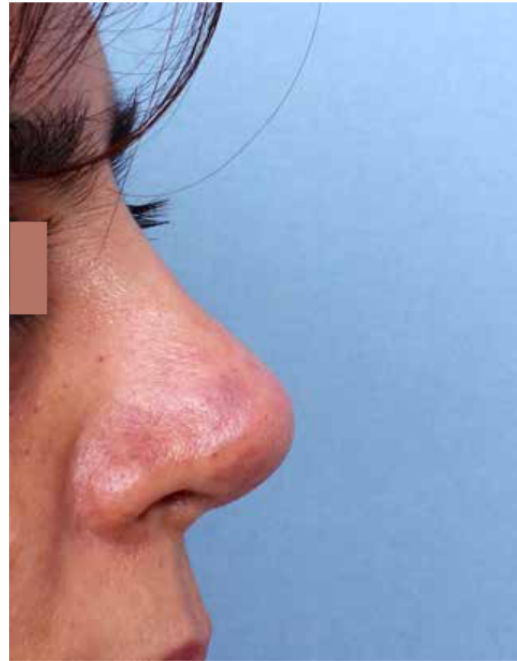Complicated cases in our series/Sex	Type of hyaluronic-filler application	Type of encountered complication	Management
Case 1/ Female	Nasolabial fold augmentation	Livedo Reticularis on the right ala nasi	Hot pack application and low dose (100 mg) acetyl salicylic acid
Case 2/ Female	Nasal tip augmentation	Livedo Reticularis on the nasal tip	Hot pack application and low dose (100 mg) acetyl salicylic acid
Case 3/ Male	Nasolabial fold augmentation	Acute cellulitic infection over the right nasolabial fold	Empiric antibiotics (amoxicillin-clavulanate 1,000 mg two times per day), antibiotic cream (fusidic acid two times per day) anti-inflammatory medication (naproxen sodium 550 mg two times per day)
Case 4/Female	Nasolabial fold augmentation	Acute cellulitic infection over the left cheek	Empiric antibiotics (amoxicillin-clavulanate 1,000 mg two times per day), antibiotic cream (fusidic acid two times per day) anti-inflammatory medication (naproxen sodium 550 mg two times per day)
Case 5/Female	Nasojugal fold erase	Prolonged infraorbital edema	Vigorous massage hyaluronidase (20-30 U)
Case 6/Female	Nasojugal fold erase	Prolonged infraorbital edema	Vigorous massage hyaluronidase (20-30 U)
Case 7/Female	Nasojugal fold erase	Right infraorbital granuloma	hyaluronidase (20-30 U), empiric antibiotics (amoxicillin-clavulanate)
Case 8/Male	Nasolabial fold augmentation	Left nasolabial granuloma	hyaluronidase (20-30 U), empiric antibiotics (amoxicillin-clavulanate)
Case 9/Female	Lip augmentation	Right upper lip granuloma and left upper lip abscess	Abscess: empiric antibiotic (amoxicillin clavulanate 1,000 mg two times per day) and surgical drainage Granuloma: hyaluronidase (20-30 U) empiric antibiotics (amoxicillin-clavulanate)
Case 10/Female	Lip augmentation	Upper lip bruising	Only follow-up
Case 11/Female	Nasolabial fold augmentation	Jowl bruising	Arnica montana herbal supplement
Case 12/Female	Chin augmentation	Chin bruising	Arnica montana herbal supplement

infectious abscess formation at the left side of the upper lip caused by HA filler application for lip augmentation were observed (Figure 4). For the treatment of the abscess, empiric antibiotic treatment (amoxicillin-clavulanate, 1,000 mg, bid) and surgical drainage were preferred, and hyaluronidase (20 to 30 U) was used for the treatment of the granuloma in the right side of the upper lip.

In three female patients, bruising was observed three to six h after the application of HA filler. The upper lip in one patient (Figure 5), the jowls in one patient, and the chin in one patient were affected. In the presence of ecchymosis in the skin, Arnica montana cream was used for the treatment. In the presence of ecchymosis in the mucosa only, the patients were convinced about the transient nature of this complication.



**Figure 1.** Livedo reticularis on right ala nasi after hyaluronic acid filler application to nasolabial fold (45 year-old female patient).



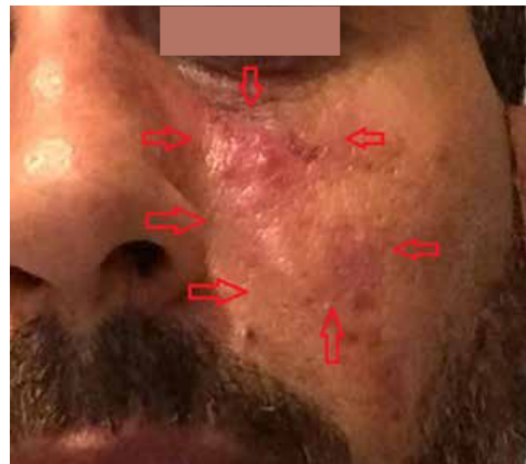**Figure 2.** Livedo reticularis on nasal tip after hyaluronic acid filler application to nasal tip (47 year-old female patient).

Infraorbital edema in two patients and granulomas in three patients were completely treated in 7 to 12 days with the use of hyaluronidase (20 to 30 U, single application).

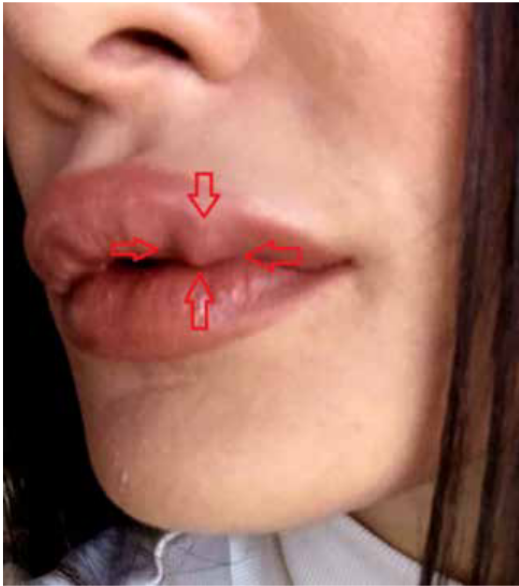
The upper lip abscess of a female patient resolved completely within 24 h with the administration of empiric antibiotic treatment (amoxicillin-clavulanate, 1,000 mg, bid) and surgical drainage.

Bruising in two of three patients totally resolved within three weeks with the use of the Arnica montana herbal supplement.

Among all patients, only 12 patients experienced HA filler-related complications, corresponding to 9.75% of all patients receiving HA filler application. The incidence of each type of complication is as follows: vascular complications 1.62%, cellulitic infections 1.62%,



**Figure 3.** Acute cellulitic infection after hyaluronic acid filler application to nasolabial fold (38 year-old male patient).

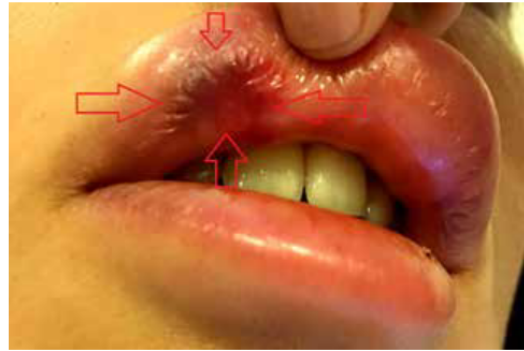


**Figure 4.** Subacute abscess formation after hyaluronic acid filler application to upper lip (39 year-old female patient).

infraorbital edema 1.62%, granuloma 2.43%, ecchymoses 2.43%, and abscesses 0.81%.

### DISCUSSION

Hyaluronic acid-based fillers are among the most frequently preferred injection materials for various rejuvenation procedures with a ratio of 78% among all dermal fillers.<sup>[3]</sup> The main reason for their preferential utilization is their relative safety. Hyaluronic acid fillers cause pure mechanical vascular obstruction, whereas non-HA fillers may induce intravascular inflammatory reactions or activate the clotting cascade,<sup>[3]</sup> leading to further unpredictable morbidities. Another reason for preferring HA fillers is the availability of effective management modalities such as hyaluronidase which hydrolyzes the filler and completely reverses the procedure. Hyaluronidase is basically an enzyme (endoglycosidase) which depolymerizes and degrades HA via hydrolyzation of the disaccharides at hexosaminidic beta-11 through beta-4 linkage.<sup>[4]</sup>



**Figure 5.** Ecchymosis formation after hyaluronic acid filler application to upper lip (28 year-old female patient).

Although hyaluronidase is licensed in many countries for its use as an enhancer for permeation of various injection materials, such as local anesthetics and subcutaneous infusions, it is mainly the off-label use of this product which is the mainstay of reversing the undesirable complications caused by the filler injections such as intravascular injection, external compression, overcorrection, asymmetry, granuloma, and nodule formation.<sup>[4]</sup>

Beyond any doubt, the most feared and devastating complications of fillers include vascular complications. The incidence of vascular occlusions (excluding blindness) is non-negligible (3/1,000), mostly occurring after injection at the glabella, ala nasi, and upper lip.<sup>[2]</sup> Its severity depends on the site of injury, health of the circulatory system, volume of injection, and formulation of the material.<sup>[3]</sup> Another essential factor in vascular complications is the thickness of the needle. As the gauge of the needle increases (thinning of the needle diameter), the possibility of vascular penetration also increases. Thicker needles may move the vessel away or may cut the vessel wall, thereby, resulting in bruising, instead of penetration. On the other hand, thin needles have the advantage of injecting smaller volumes, which is another important issue to prevent vascular occlusion by a filler. It is also essential to be familiar with the anatomy of the face, particularly the vascular system. The presence of scars at the site of injection may also increase the risk of

vascular penetration, since scars stabilize and fix arteries in place, making them easier to be penetrated.<sup>[3]</sup> One possible explanation to the circulatory problem which was observed after filler application to the nasal tip in one of our patients may be the presence of intensive scarring due to three previous rhinoplasties.

In both patients with circulatory complications, our self-criticism depends on the possibility of a bolus injection of HA filler (>0.1 mL) to the same place in a single syringe push. In one patient having alar livedo after nasolabial fold HA application, venous obstruction was the probable cause of the complication. However, in another patient having nasal tip livedo, most probably the volume of the filler inside the limited space made excess pressure to the skin and scarred the superficial musculoaponeurotic system tissue. Fortunately, these complications were self-limited and recovered after conservative measures, such as warm compression and oral low-dose salicylic acid (100 mg). The areas prone to embolism leading to skin necrosis are glabella, nasal tip, and lips.<sup>[4]</sup> It has been reported that less than 0.1 mL of filler application for each point of injection should be used, as the filler volume less than 0.1 mL can hardly, if ever, occlude any vessel. It is also recommended to change the needle if any degree of the clog is recognized, since a clog possibly caused by partial blockage of the needle may increase the required force to push the syringe forward. This force may result in the accidental release of a large bolus of the filler material which may cause vascular occlusions in a very dangerous fashion.<sup>[3]</sup> Retinal artery occlusion is the most feared of all vascular complications. The retrograde progression of the filler in the arterial lumen under high pressure is the main cause. The areas most prone to embolism leading to blindness are the nose, nasolabial fold, forehead, and glabella.<sup>[4]</sup> Vision impairment and blindness due to periocular embolism is a medical emergency presenting with acute ocular pain. The patient must be immediately transferred to a hospital setting and appropriate management by retrobulbar injection of hyaluronidase (150-200 U in 2 to 4 mL of diluent) via the inferolateral orbital access must be performed during transportation.

Nonetheless, complete recovery in these cases is rare.<sup>[5]</sup>

Compared to ocular ischemia, cutaneous ischemia is less of an emergency, but it should also be treated within less than 24 h.<sup>[3]</sup> The use of blunt cannulas in high-risk regions, such as glabella, nose, and nasolabial fold is recommended to reduce the risk of injury to the vessels.<sup>[1]</sup> A double-blind, randomized study demonstrated fewer side effects in the nasolabial fold, when the cannulas were used, rather than the needles.<sup>[6]</sup>

Acute infections are first treated with empiric antibiotic treatment (i.e., amoxicillin-clavulanate, cephalosporin, cephalexin, or ciprofloxacin). However, if an empiric antibiotic is not effective, culture-directed therapy is highly recommended. If there is an abscess formation, it should be surgically drained. For the prevention of infection, the use of an appropriate antiseptic solution, make-up free application, use of disposable, non-sterile gloves, and sterile dressing trays and drapes are all recommended. In case of herpes virus history, proper prophylaxis is recommended. In two of our infected patients, empiric antibiotic treatment alone was sufficient to control the infection and, in one patient with upper lip abscess formation, surgical drainage combined with empiric antibiotic treatment was effective.

Periorbital region is prone to edema formation. Even a very small amount of filler placed into the periorbital space may cause severe, persistent eye bags which are repeatedly observed to last for much longer than the usual duration of dermal fillers, often extending into several years. This may be due to reduced breakdown or metabolism of HA filler products within this anatomical space, where the human vitreous body lays, which primarily consists of endogenous HA.<sup>[2]</sup> In two of our patients with prolonged periorbital edema, one application of hyaluronidase (20 to 30 IU) was highly effective for treatment. Although a certain amount of prudence should be maintained during the procedure, it is comforting to know that hyaluronidase would not affect the body's own HA.<sup>[2]</sup> Therefore, further hollowing or volume loss is not expected after reversal of swelling

with the application of the enzyme. Granuloma formation, a fundamental sign of an exaggerated local immune response, is the most common adverse event associated with all types of fillers. Some authors have advocated that biofilm with low-grade bacterial colonization may play a significant role in granuloma formation by inducing an immunological reaction.<sup>[2]</sup> A biofilm is an aggregate of self-encapsulated microorganisms in a polymeric matrix, irreversibly adherent to a living or inert surface. Biofilms are difficult for oral antibiotics to penetrate, and they can be difficult to culture. They may also contain bacteria, protozoa, or fungi in case of a low-grade infection which clinically seeds the local area and can even induce a systemic infection. Biofilms are known to be associated with foreign body granulomas.<sup>[2]</sup> Hyaluronic acid is derived from a fermentation event of bacteria, which may be a source of impurities. Similarly, breakdown products of HA fillers *in vivo* may elicit hypersensitivity reactions.<sup>[7]</sup> If the granuloma is fluctuant, incision, drainage, and antibiotic treatment are recommended. If it is non-fluctuant, empiric antibiotic, hyaluronidase, and steroid use can be chosen. In case of repeated failure of treatment, excision of the granuloma is recommended.<sup>[7]</sup> Application of hyaluronidase combined with empiric antibiotic treatment was effective in our patients with granuloma formation.

Finally, bruising, the most benign complication of filler application may also be the center of a substantial amount of patient complaints due to transient social impairment. The target patient population seeking non-invasive cosmetic rejuvenation, such as fillers, are usually extremely self-conscious of their physical appearance and, although a relatively benign complication, bruising may cause utmost disappointment and a marked decrease in patient satisfaction. Keeping this in mind, necessary precautions should also be taken to prevent this seemingly minor adverse effect to enhance the quality of overall patient experience. A thorough history of use of any medications, such as anticoagulants or non-steroidal anti-inflammatory drugs, should be taken before the procedure, as well as consumption of any herbal infusions, green

tea or vitamins which interfere with the clotting cascade. Immediate pressure, rather than cold therapy, remains the mainstay of prevention of bruising. Therefore, enough time should be provided for each application region with optimal management of patient appointments to prevent rushing of the procedure. Once bruising occurs, it is helpful to prescribe topical creams such as Arnica montana herbal supplement to accelerate healing, as well as to warn the patient against sun exposure until the bruise completely recovers, which may otherwise cause permanent pigmentation on the skin.

In conclusion, our study results show that fillers are not completely innocent products. Success with utmost patient satisfaction and minimum complications strictly depend on the specific rules that one should respect. We recommend that these materials should be used in experienced hands in accordance with the relevant regulations.

#### Declaration of conflicting interests

The authors declared no conflicts of interest with respect to the authorship and/or publication of this article.

#### Funding

The authors received no financial support for the research and/or authorship of this article.

#### REFERENCES

1. Vedamurthy M. Beware What You Inject: Complications of Injectables-Dermal Fillers. *J Cutan Aesthet Surg* 2018;11:60-6.
2. Rzany B, DeLorenzi C. Understanding, Avoiding, and Managing Severe Filler Complications. *Plast Reconstr Surg* 2015;136:196-203.
3. DeLorenzi C. Complications of injectable fillers, part 2: vascular complications. *Aesthet Surg J* 2014;34:584-600.
4. Buhren BA, Schrupf H, Hoff NP, Bölke E, Hilton S, Gerber PA. Hyaluronidase: from clinical applications to molecular and cellular mechanisms. *Eur J Med Res* 2016;21:5.
5. Carruthers JD, Fagien S, Rohrich RJ, Weinkle S, Carruthers A. Blindness caused by cosmetic filler injection: a review of cause and therapy. *Plast Reconstr Surg* 2014;134:1197-201.
6. Hexsel D, Soirefmann M, Porto MD, Siega C, Schilling-Souza J, Brum C. Double-blind, randomized, controlled clinical trial to compare safety and efficacy of a metallic cannula with that of a standard needle for soft tissue augmentation of the nasolabial folds. *Dermatol Surg* 2012;38:207-14.

7. Signorini M, Liew S, Sundaram H, De Boule KL, Goodman GJ, Monheit G, et al. Global Aesthetics Consensus: Avoidance and Management of

Complications from Hyaluronic Acid Fillers- Evidence- and Opinion-Based Review and Consensus Recommendations. *Plast Reconstr Surg* 2016;137:961-71.