



Increased cerebral blood flow in the right anterior cingulate cortex and fronto-orbital cortex during go/no-go task in children with ADHD

Muharrem Burak Baytunca , Blaise de Frederick , Gul Unsel Bolat , Burcu Kardas , Sevim Berrin Inci , Melis Ipci , Cem Calli , Onur Özyurt , Dost Öngür , Serkan Süren & Eyüp Sabri Ercan

To cite this article: Muharrem Burak Baytunca , Blaise de Frederick , Gul Unsel Bolat , Burcu Kardas , Sevim Berrin Inci , Melis Ipci , Cem Calli , Onur Özyurt , Dost Öngür , Serkan Süren & Eyüp Sabri Ercan (2021): Increased cerebral blood flow in the right anterior cingulate cortex and fronto-orbital cortex during go/no-go task in children with ADHD, Nordic Journal of Psychiatry, DOI: [10.1080/08039488.2020.1864775](https://doi.org/10.1080/08039488.2020.1864775)

To link to this article: <https://doi.org/10.1080/08039488.2020.1864775>



Published online: 07 Jan 2021.



Submit your article to this journal [↗](#)



Article views: 24

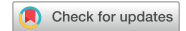

View related articles [↗](#)




View Crossmark data [↗](#)

RESEARCH ARTICLE



Increased cerebral blood flow in the right anterior cingulate cortex and fronto-orbital cortex during go/no-go task in children with ADHD

Muharrem Burak Baytunca^a, Blaise de Frederick^b, Gul Unsel Bolat^c, Burcu Kardas^d, Sevim Berrin Inci^e, Melis Ipci^f, Cem Calli^g , Onur Özyurt^h, Dost Öngürⁱ, Serkan Süren^j and Eyüp Sabri Ercan^j

^aDepartment of Psychiatry, University of Utah, Salt Lake City, UT, USA; ^bMcLean Imaging Center, Department of Psychiatry, Harvard University, MA, USA; ^cDepartment of Child and Adolescent Psychiatry, Balikesir University, School of Medicine, Balikesir, Turkey; ^dDiyarbakir Gazi Yasargil Research and Training Hospital, Department of Child and Adolescent Psychiatry, Diyarbakir, Turkey; ^eDepartment of Psychology, Isik University, Istanbul, Turkey; ^fClinical Psychology Department of Hasan Kalyoncu University, Gaziantep, Turkey; ^gDepartment of Radiology, Ege University, Izmir, Turkey; ^hTelemed, Bogazici University, Teknopark, Istanbul, Turkey; ⁱDivision of Psychotic Disorders, McLean Hospital, Harvard Medical School, Belmont, Massachusetts, USA; ^jDepartment of Child and Adolescent Psychiatry, Ege University, School of Medicine, Izmir, Turkey

ABSTRACT

Objective: Arterial spin labeling (ASL) is a relatively new imaging modality in the field of the cognitive neuroscience. In the present study, we aimed to compare the dynamic regional cerebral blood flow alterations of children with ADHD and healthy controls during a neurocognitive task by using event-related ASL scanning.

Methods: The study comprised of 17 healthy controls and 20 children with ADHD. The study subjects were scanned on 3 Tesla MRI scanner to obtain ASL imaging data. Subjects performed go/no-go task during the ASL image acquisition. The image analyses were performed by FEAT (fMRI Expert Analysis Tool) Version 6.

Results: The mean age was 10.88 ± 1.45 and 11 ± 1.91 for the control and ADHD group, respectively ($p = .112$). The go/no-go task was utilized during the ASL scanning. The right anterior cingulate cortex (BA32) extending into the frontopolar and orbitofrontal cortices (BA10 and 11) displayed greater activation in ADHD children relative to the control counterparts ($p < .001$). With a lenient significance threshold, greater activation was revealed in the right-sided frontoparietal regions during the go session, and in the left precuneus during the no-go session.

Conclusion: These results indicate that children with ADHD needed to over-activate frontopolar cortex, anterior cingulate as well as the dorsal and ventral attention networks to compensate for the attention demanded in a given cognitive task.

ARTICLE HISTORY

Received 16 November 2020
Revised 6 December 2020
Accepted 11 December 2020

KEYWORDS

Attention deficit hyperactivity disorder; ADHD; children; arterial spin labeling; ASL; perfusion fMRI

1. Introduction

Attention deficit hyperactivity disorder is a neurodevelopmental disorder with a prevalence of 3% to 5% among children (APA). The specific brain network abnormalities underlying the pathophysiology of ADHD has not yet been found. Thus far, researchers have reported abnormalities in medial and orbitofrontal, parietal, cingulate cortices during the cognitive tasks in functional magnetic resonance imaging (fMRI) studies [1]. However, the number of studies that have investigated the dynamic regional cerebral blood flow (rCBF) alterations of individuals while completing attention tasks is limited. In several single-photon emission computerized tomography (SPECT) studies, researchers have reported controversial findings on rCBF alteration in bilateral frontal and parietal cortices as well as in the cingulate cortex in adults during attention-related tasks [2–7]. Altered rCBF during resting state was also reported in children with ADHD relative to controls. Researchers have reported decreased rCBF in the right frontal (BA10 and 11) and temporal areas (BA21) but

increased rCBF in bilateral parietooccipital regions in children with ADHD during resting state SPECT scan [8,9]. The increase of rCBF in right-sided frontal regions after methylphenidate treatment was also observed in children with ADHD relative to controls [10].

The attention network system is comprised of two networks that dynamically interact with each other: dorsal and ventral attention networks. The dorsal system is bilaterally located in each hemisphere and consists of two core components: dorsal parietal region (in particular superior parietal lobule (SPL) and intraparietal sulcus (IPS) and the junction of precentral gyrus) and superior frontal gyrus (frontal eye field, FEF). The dorsal attention network (DAN) seems to be capable of the production and maintenance of endogenous signals based on ongoing goals or preexisting information of contingencies [11,12]. The ventral attention network (VAN) consists of the temporoparietal junction (TPJ) and ventral frontal cortex and is unilaterally located in the right hemisphere. The temporoparietal junction (TPJ) is anatomically located at the intersection of the posterior end of the

temporal sulcus, the inferior of parietal lobule and the lateral occipital cortex. The right-sided insula, supramarginal gyrus (TPJ), frontal gyrus (superior, middle and inferior), middle temporal gyrus and precuneus are the foci identified as related to ventral network [11–13]. From a clinical perspective, the ventral attention network is primarily engaged with the relevant salient stimuli, regardless of its distinctiveness. In neuroimaging studies, it was found that this network is also associated with an abrupt change of sensory stimuli, and onset and offset of given tasks [13–15].

Arterial Spin Labeling (ASL) is a relatively new brain imaging modality in the field of psychiatry. ASL is utilized to quantify brain tissue perfusion by using labeled arterial blood as an endogenous tracer [16]. The ASL method was reported to induce less across-subject variability and long-term reproducibility [17,18]. Moreover, when compared to functional magnetic resonance imaging (fMRI), ASL was shown to be more sensitive to the tonic changes – rather than phasic responses – of brain metabolism to a given cognitive task [17,19,20]. However, there are studies resulted with tonic blood flow changes in minutes during a given cognitive task and slow continuous changes can be detected in ASL imaging [9,21–23]. To date, few ASL findings relating to the attention system have been published. Increased rCBF during the resting state ASL scan was found in the left caudate, inferior/medial frontal gyrus and bilateral cingulate gyrus and precuneus in adult subjects with ADHD relative to controls [24]. Further, increased rCBF in the right-sided frontoparietal areas including medial (BA8, 9) and inferior frontal gyrus, occipital gyri (BA18), bilateral anterior cingulate (BA32) was reported in several ASL studies utilizing with sustained attention and vigilance tasks [9,21,22]. However, these prior studies were conducted on adults and most did not include ADHD subjects. To the best of our knowledge, this is the first event-related ASL study comparing children with ADHD and control subjects in the literature.

In the present study, the participants were required to complete the go/no-go task. Challenger to attention maintenance in this task is the no-go stimulus, to which responders are required to not hit the button. It is proposed that the no-go stimulus is a predictor of response inhibition and the go paradigm in the same task is related to the sustained attention performance. In a meta-analysis of fMRI studies comparing children with and without ADHD during go/no-go task, researchers have reported greater activation in right medial frontal gyrus in children with ADHD but greater activation in the right superior frontal gyrus in the control group [25]. Given that dorsal attention network is activated by the expectation of seeing particular object at particular location in addition to maintenance of sustained attention, this network was expected to be activated in the present study. The ventral attention network was also expected to be activated since this network co-activates with DAN during reorienting, which was the case for switching from 'go' to 'no-go' task. In our study, we hypothesized areas implicated in the dorsal and ventral attention networks (right hemisphere dominant frontal, parietal areas) might show distinctive regional

cerebral blood flow during a cognitive task in children with ADHD relative to the control counterparts.

2. Material and method

2.1. Subjects


In the present study, participants were drawn *via* clinical referrals from children admitted to the hospital by their parents or teachers for a possible ADHD diagnosis. The study was approved by the hospital ethical committee. Written consent was obtained from both the subjects and their parents. The current study was compliant with the ethical standards of Helsinki declaration and its later amendments. Subjects were required to be between the ages of 8 and 18 years old, right-handed, free of any psychiatric and medical comorbidity, possess an intelligence quotient (IQ) score above than 80, and be drug-naïve. The control subjects were drawn from the same community and were required to be free of any psychiatric disorder in addition to the aforementioned criteria. Psychiatric interviews of the ADHD and control subjects were conducted using the Kiddie-Schedule for Affective Disorders and Schizophrenia, present and lifetime version (K-SADS-PL), and the diagnoses were made in accordance with DSM-V criteria [26].

2.1.1. ADHD subjects

The DSM-IV-based Disruptive Behavior Disorders Rating Scale (DBDRS-parent and teacher form) was utilized to diagnose for ADHD. This scale contains nine items for the inattention and hyperactivity/impulsivity dimensions. All the items have four possible answers ranging from 1 (not at all), 2 (sometimes), 3 (often) and 4 (very often); a symptom was considered to be present if 3 or 4 was endorsed on any item. The DSM-IV-TR requires the presence of at least 6 symptoms out of the 9 items in either the inattention or hyperactivity/impulsivity dimensions to make a diagnosis of ADHD [26,27]. The Child Behavior Checklist (CBCL) and Teacher Report Form were also obtained to support the diagnosis and exclude any comorbid mental disorders [28].

2.2. Go/no-go paradigm


The go/no-go test is widely used in the neuroimaging research of ADHD. The primary utility of the paradigm is to assess the response inhibition. Subjects were required to respond to go cues as fast as they can while also withholding from responding when the no-go cue is presented. The go cues in the present study were several different images of 'Spider-man', and pictures of the cartoon character 'Goblin' were shown as the no-go stimulus. All the go and no-go cues were displayed after the fixation cross ('+') on a black screen (Figure 1). The stimuli were displayed to the participants by a mirror fixed in the head coil. The presentation ratio for the go and no-go trials were 0.8 and 0.2, respectively. However, the presentation of 6 or more subsequent go cues in a row was not allowed. The trial started with 15 s of fixation cross which was followed by



Trial started with 15 s of fixation cross




*The various images of spider-man were shown as "go" clue.
The participants were asked to hit the button when go stimulus was presented
The duration of each spider-man images was 500 ms in each trial.*



The duration of fixation cross between the stimulus was 1000 ms

The inter stimulus interval was set as 1500 ms



*The various images of goblin were shown as "no-go" clue.
The participants were asked to no to hit the button
when no-go stimulus was presented
The duration of each goblin images was 500 ms in each trial*

Figure 1. Depiction of go and no-go trial.

140 go or no-go stimuli. In each trial, the stimulus (Spiderman or Goblin) was displayed for a duration of 500 ms and the duration of fixation period was 1000 ms. The inter stimulus interval was set as 1500 ms. Participants responded to the go stimuli by hitting the button on a joystick in held in their right hand with their right thumb or index finger. Prior to scanning, the subjects were given instructions and allowed to play a trial of the task. Since the ASL scanning of the subjects was a component of our previous study [29], the participants also completed a go/ no-go task during a fMRI session, which took 339 s, prior to

the ASL scanning. Therefore, all subjects had completed this task both as a trial session and during fMRI scanning before the ASL scan.

2.3. Image acquisition

The study subjects were scanned on 3 Tesla MRI scanner with 12-channel head coil (Siemens Allegra, Siemens Medical Systems). Initially, T1-weighted anatomical scans of the subjects were obtained by using MPRAGE sequence (TR = 2.5s, TE = 2.71 ms, TI= 900 ms; 176 sagittal slices $1 \times 1 \times 1 \text{ mm}^3$

isotropic voxels). For ASL scans, 179 dynamic volumes were obtained by using pulsed labeling and Echo-Planar Imaging (EPI) readout with the parameters TR = 2500 ms, TE = 11 ms, flip angle 90°, matrix 64 × 64, field of view 192 mm, 14 transverse slices, 6 mm slice thickness, 1.5 mm inter-slice gap.

2.4. Image analysis

The image analyses were performed by FEAT (fMRI Expert Analysis Tool) Version 6. The functional images of the subjects were realigned and then registered to each subject's anatomical T1 weighted MR data. Spatial smoothing using a 5-mm full-width at half-maximum Gaussian kernel was applied during this process. For each subject, head motion was analyzed with MCFLIRT, and those with excessive head motion artifact (2 subjects in ADHD group and 6 subjects in the control group) were not included in further analyses [30]. Individual functional images were registered to the standard Montreal Neurological Institute T1 (MNI152) template.

2.5. Statistical analysis

In the first level analysis, 3 voxel-wise statistical analyses were conducted by using the general linear model (GLM) for each subject: pairwise control-tag comparisons of the entire MRI scanning (including go and no-go sessions), only the go task pairs, and only no-go task pairs. Temporal filtering was not utilized. The threshold for the statistical significance was set for greater than 3.1 for z-score and $p < .05$ for cluster significance. This threshold was also applied for the group level comparison. However, a separate additional analysis with a z-score threshold of 2.3 and $p < .05$ for cluster significance was also applied for go and no-go tasks, as elaborated on in the discussion section. In the group comparisons, we compared the entire scan, only the go pairs, and only the no-go pairs,

Table 1. Socio-demographic and behavioral results of the diagnostic groups.

	Control	ADHD	<i>p</i> -value
Gender			
Female	5	1	.075
Male	12	19	
Age	10.88 ± 1.45	11 ± 1.91	.112
WISC-R	115 ± 11.11	110 ± 16.70	.882
ADHD scale (parent rated)			
Inattention	1.35 ± 2.76	13.80 ± 4.49	<.000
Hyperactivity-Impulsivity	0.82 ± 1.59	11.50 ± 8.75	<.000
Oppositional defiant disorder	0.70 ± 1.21	3.30 ± 4.30	.024
ADHD scale (teacher rated)			
Inattention	0.94 ± 1.88	14.0 ± 6.24	<.000
Hyperactivity-Impulsivity	0.70 ± 1.21	10.70 ± 7.94	<.000
Oppositional defiant disorder	0.11 ± 0.48	2.70 ± 4.76	.187

between the ADHD and control groups using FSL FLAME (FMRIB's Local Analysis of Mixed Effects). The analysis was also repeated using permutation testing in randomize (also part of FSL) as a check on the significance thresholds (see Discussion). Anatomical coordinates of the activated brain areas were given in Talairach Daemon coordinates [31]. We did not perform resting state ASL scanning, which is discussed later in this paper. Therefore, we only compared the activation changes between groups for go only, no-go only, and all conditions.

3. Results

In the present study, the male-to-female ratio was 12/5 in the control group and 19/1 in the ADHD group ($p = .075$). The mean age of control and ADHD groups were 10.88 ± 1.45 and 11 ± 1.91 , respectively ($p = .112$). The mean WISC-R results of control and ADHD groups were not also found statistically different (115 ± 11.11 vs. 110 ± 16.70 , $p = .882$).

3.1. Behavioral results

The subdomains of the ADHD scale rated by parents statistically differed between the groups (Table 1). The mean inattention score was 13.80 ± 4.49 in the ADHD group and 1.35 ± 2.76 in the control group ($p < .000$). The hyperactivity-impulsivity score was 11.50 ± 8.75 in the ADHD group and 0.82 ± 1.59 in the control group ($p < .000$). The mean oppositional defiant disorder score was 3.30 ± 4.30 in the control and 0.70 ± 1.21 in the ADHD group ($p = .024$). The mean inattention subscale score by teachers was 14.0 ± 6.24 in the ADHD group and 0.94 ± 1.88 in the control group ($p < .000$). The mean hyperactivity-impulsivity score was 10.70 ± 7.94 in the ADHD group and 0.70 ± 1.21 in the control group ($p < .000$). The mean oppositional defiant disorder score was 2.70 ± 4.76 in the ADHD group and 0.11 ± 0.48 in the control group ($p = .187$).

3.2. Imaging results

When combining the go and no-go conditions, the between-group analyses contrasting the ADHD and control groups revealed statistically significant activation in the right anterior cingulate cortex (BA32) extending to the right medial frontal gyrus BA 10 and BA 11 from the voxel-based analysis (see Table 2 for voxel sizes and coordinates and Figure 2 for activation areas). Notably, no brain areas were found to be more

Table 2. The ASL comparison of the diagnostic groups during entire scan.

Contrast	Region	Talairach x,y,z coordinates	Z score	<i>p</i> -value	Voxel number
ADHD > Control					
	Anterior Cingulate Cortex BA32	10, 38, -16	4.42	<.001*	630
	Medial Frontal Cortex BA11	4, 50, -26	4.24		
	Medial Frontal Cortex BA11	4, 34, -24	3.91		
	Medial Frontal Cortex BA10	4, 60, -8	3.77		
	Medial Frontal Cortex BA10	14, 62, -8	3.67		

Please note that there was no greater brain region activation in any brain area in the control subjects than ADHD counterparts. BA: Brodmann Area. *Indicates 0.00000221.

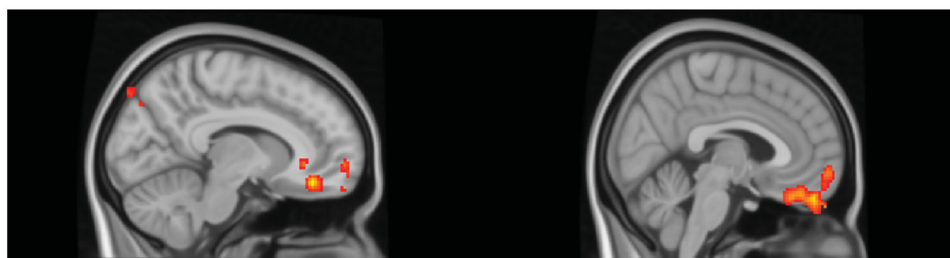


Figure 2. Anterior Cingulate Cortex (right) and medial frontal cortex (right) are the identified areas showing greater activation in children with ADHD relative to control counterparts.

Table 3. The ASL contrast of the diagnostic groups during go pairs.

Contrast	Region	Talairach x,y,z coordinates	Z score	p-value	Voxel number
ADHD > Control (go task)					
	R Superior Parietal Lobule BA7	18, -67, 60	3.89	<.001*	2307
	R Parietal Lob, Precuneus	18, -72, 58	3.79		
	R Middle Frontal Gyrus BA10	42, 54, 22	3.91	<.001 **	1606
	R Inferior Frontal Gyrus	56, 28, 12	3.61		
	R Temporal Lob BA42	66, -18, 12	3.42	.00366	744
	R Inferior Parietal Lob	64, -22, 26	3.36		
	R Supramarginal Gyrus	52, -36, 36	3.26		
	R Parietal Lobule BA40	58, -36, 52	3.11		
	R Inferior Parietal Lobule BA40	52, -32, 58	3.09		

Please note that there was no greater brain region activation in any brain area in the control subjects than ADHD counterparts. In this contrast, cluster threshold was decreased from 3.1 to 2.3. BA: Brodmann Area, R: right. *.0000000596, **.00000507.

Table 4. The ASL contrast of the diagnostic groups during no-go pairs.

Contrast	Region	Talairach x,y,z coordinates	Z score	p-value	Voxel number
ADHD > Control (no-go task)					
	L Parietal Lob, Precuneus, BA7	-20, -76, 50	3.53	.000393	1048
	R Occipital Lob, Cuneus, BA19	6, -80, 40	3.5		
	R Parietal Lob, Precuneus, BA19	10, -82, 48	3.47		
	R Parietal Lob, Precuneus, BA7	-18, 70, 46	3.46		

Please note that there was no greater brain region activation in any brain area in the control subjects than the ADHD counterparts. In this contrast cluster threshold was decreased from 3.1 to 2.3 (see Discussion). BA: Brodmann Area, R: right L: left.

greatly activated in control subjects over their ADHD patient counterparts.

3.3. Go task results

The voxel-based analysis revealed no significant activation difference between the groups. However, when a lenient cluster threshold (2.3) was employed, three activation clusters were identified in those with ADHD. The first cluster included right superior parietal lobule (BA7) and right precuneus. The second cluster was comprised of right middle frontal (BA10) and inferior frontal gyrus. The last cluster included the right-sided temporal lobe (BA42), inferior parietal lobe (BA40) and supramarginal gyrus. The voxel sizes and coordinates were given in Table 3. The control group showed no greater activation than the ADHD group in any brain region at the threshold of 3.1 or 2.3.

3.4. No-go task results

Again, we failed to find any brain activation differences between groups at the voxel-based analysis level. When the cluster threshold was decreased to 2.3, left precuneus (BA7) and right cuneus and precuneus (BA19 and BA7) areas

showed statistically significant activation in the ADHD group when compared to the control group (please refer to Table 4 for voxel sizes and coordinates).

4. Discussion

In the present study, we aimed to assess and compare the regional cerebral blood flow (rCBF) changes between children with ADHD versus healthy controls during a cognitive task. This study has provided some insight into rCBF alterations in children with ADHD by implementing a novel imaging method, namely Arterial Spin Labeling. To date, there are only a handful of ASL studies investigating the physiological response of brain regions to the certain attention tasks. Moreover, this is the first event-related ASL study comparing children with ADHD to healthy counterparts in the literature.

The most striking finding of the present study was the increased rCBF in the right anterior cingulate cortex (ACC) (BA32), frontopolar and orbitofrontal cortices (BA 10,11) in the ADHD group during the go/no-go task. It has been reported that ACC engages with attention allocation, conflict resolution, novelty detection and response inhibition [32–34]. In several meta-analyses, hypo-activation in rACC was shown in children with ADHD [25,35–37]. In concurrence with the

findings of our study, researchers have also reported decreased functional connectivity between dorsal ACC and precuneus in adults with ADHD [38]. The findings of the present study indicate that ADHD children displayed greater rACC activation than their control counterparts to compensate for attention demand during the given task.

Another important finding of the present study is that, children with ADHD displayed greater activity in frontopolar cortex (BA10), bilateral precuneus which is a component of default mode network (DMN) [39,40], as well as orbitofrontal cortex (BA11) during the entire task. Enhanced activation in BA10/32 was reported in children and adolescents with ADHD [41,42]. In addition to the previous studies, hypoperfusion in R MFG (BA10) as well as hyperperfusion in the posterior brain areas during resting state in children with ADHD were found [8,10]. Schweitzer has reported rCBF increase in precuneus (BA7), R middle frontal gyrus (BA10) during a working-memory task in men with ADHD [43]. Sturm reported right-sided rCBF increase in the anterior cingulate cortex (BA32), right middle frontal gyrus (BA9, 10), inferior parietal lobule, middle temporal gyrus and left inferior frontal gyrus in healthy adults during an alertness task using positron emission tomography (PET) [7]. Significant rCBF increase in the right BA 10 during go/no-go task was also reported in healthy subjects [44]. Although, the go/no-go is a task of inhibitory control, which has been proposed to be impaired in those with ADHD, stimulus selection, attention maintenance and response selection are important components of the task [45]. Broadman area 10 was cytoarchitecturally and functionally subdivided into two different poles: Fp1 and Fp2, the former being involved in cognition, information processing, prepotent response inhibition and working memory [46–49]. The results of our study indicate that children with ADHD require to rely on more diffuse neural networks involving in working memory, attention shifting, conflict resolution, in addition to ventral and dorsal attention networks, to challenge with an attention demanding task. Supporting the hypothesis of poor control of response inhibition in ADHD [50–54], we observed increased activity in OFC, which was shown to be associated with inhibitory control of behavior which enables adaptive behavioral response in the setting of changing environment, of which impairment was shown to be associated with impulsive decision making and maladaptive behavior [55–58]. It was reported that ADHD children display reduced activation in OFC during tasks implicating reward-related decision making [1,59,60]. Given that our subjects were not rewarded during the go/no-go task, we can speculate that the enhanced activation in OFC seems to be contributing to impulsive decision making as a result of overactivation of this region compared to healthy counterparts. Further ASL studies comparing the effect of neurocognitive tasks of inhibitory control and reward processing are warranted.

The dorsal attention network engages with goal-driven stimuli during a given task. Its core regions are the dorsal parietal cortex (particularly superior parietal cortex and intraparietal sulcus) and dorsal frontal cortex near precentral gyrus in each hemisphere [11,12]. This network is pre-

activated in the likelihood of incoming stimuli with certain features and/or context. In our study, subjects were required to produce and maintain their endogenous attention signal in order to hit the button across go trials, a task that which mainly involves the dorsal attention network. Although we were not able to see any statistically significant difference between the diagnostic groups when applying a cluster significance threshold of 3.1, a more lenient threshold of 2.3 enabled us to observe consistent findings with this hypothesis. It is worth noting that the use of 3.1 as a significance threshold is a recent development due to Eklund's work in BOLD fMRI [61]. It has yet to be established whether the higher threshold is necessary for ASL analyses. In order to explore this, we repeated our analysis using permutation testing in randomize (also part of FSL), and found that the FLAME and randomize maps were essentially identical at the $z = 2.3$ significance level. This would seem to indicate that non-Gaussian shaped spatial autocorrelation is not the problem in ASL data that it is in BOLD fMRI, so 2.3 would seem to be the appropriate significance level for ASL analyses using FLAME. This deserves further study.

We identified three right-sided core clusters in the superior parietal lobe (BA7), middle/inferior frontal gyrus, and temporoparietal areas – including the posterior transverse temporal lobule (BA42), inferior parietal lobule (BA40) and supramarginal gyrus – in children with ADHD during the go session. It should be cautiously noted that the two latter clusters are within the ventral attention network. The ventral network consists of the TPJ (at the intersection of the posterior side of the superior temporal gyrus, inferior parietal lobule, and lateral occipital cortex), the ventral parts of supramarginal gyrus and middle/inferior frontal gyrus, as well as the frontal operculum and anterior insula. The ventral attention network is activated along with the dorsal attention network when a behaviorally relevant stimulus is presented [11,14]. In a visual sustained attention task-integrated ASL study, researchers have reported greater activation in the right middle frontal gyrus (BA8,9) bilateral occipital gyrus (BA18), right cuneus (BA18) and the left cingulate gyrus (BA32) when compared to the resting state in adults [9]. Additionally, a significant rCBF increase was reported in the right middle/inferior frontal gyrus, right inferior parietal lobe, bilateral supplementary motor area/anterior cingulate cortex, bilateral basal ganglia/insula and the left sensorimotor cortex during a sustained attention task in an ASL study.

Importantly, we identified significant activation in the left precuneus extending to the right precuneus and bilateral cuneus during the no-go condition when a lenient threshold (2.3) was applied. The precuneus was reported to be a cross-network connector between the default and dorsal attention networks and flexibly engaged with executive control [62,63]. The precuneus was also shown to possess extensive connections with the lateral parietal areas (superior, inferior parietal areas), FEF and anterior cingulate cortex; other than the FEF, these areas were all found to be greatly activated in children with ADHD relative to the control subjects during the go/no-go task. Several neuroimaging studies have indicated that the precuneus co-activates in concert with lateral

parietal areas for visually guided behavior, attention shifting and spatial attention [64–69]. In the literature, there are event-related fMRI studies indicating abnormal precuneus activation in those with ADHD [59,70,71]. In an event-related fMRI meta-analysis, the authors reported increased bilateral activity in the precuneus (BA7), posterior cingulate cortex, and cuneus (BA7) in children with ADHD relative to the control group. However, the same authors theorized this abnormal activity pattern was the result of defective deactivation of the default mode network [72]. Notably, it was also stated that the left precuneus co-activates within the default mode network during resting state but enhances its activity during a given task [62]. With a similar but not identical neuropsychological task (go, no-go and lure condition), Wang reported increased activation in precuneus during the no-go task in children with ADHD when compared to the control subjects [73]. The greater fMRI activation in bilateral precuneus along with frontoparietal regions in child ADHD patients during the go/no-go task was also indicated. The same authors also reported increased activation in the precuneus and frontoparietal areas during no-go session over go session in children with ADHD [42]. Therefore, the increased rCBF in the bilateral precuneus in children with ADHD during the no-go trials might be related to the response inhibition and shifting attention. Since we did not observe significantly increased precuneus activation between the ADHD vs control group during the go trials or overall task, the results might be suggestive of the maintenance and shifting of attention rather than a default mode network abnormality.

Even though, we found consistent findings with our hypothesis, the activation areas in the present study were not widespread as is the ADHD fMRI findings. It should be noted that ASL is sensitive to the tonic components of maintaining attention rather than phasic ones over time [17].

5. Limitations

One of the major limitations of this study was the lack of resting state CBF quantification, which prevented us from comparing the baseline rCBF patterns in children with and without ADHD. Since the deactivation of default mode network is related to improved performance in a given attention-demanding cognitive test, our study did not enable us to observe the any potentially dynamic response of the deactivated areas during the go/no-go task. Additionally, the lack of resting state CBF also inhibited us from evaluating the normal neurophysiological response to the given attention task and comparing such findings to those previously published in the literature. The most noticeable finding of our study was increased rCBF in the frontopolar cortex (BA10, 11) and cingulate cortex along with dorsal attention network as well as ventral attention network when a lenient threshold applied. Since we were not able to directly compare the resting and task-related rCBF changes, significant rCBF increase in these areas in ADHD group might arise from increased resting state rCBF, dynamically increased rCBF

response to attentional demand, or both. Even though increased rCBF in MFG is consistent with our hypothesis, itself based on prior dorsal and ventral attention network literature findings, future studies are warranted to disentangle this finding. Another major limitation of the present study is the gender imbalance across and between groups. Female subjects were notably underrepresented in each diagnostic group. Hence, the contribution of gender to the ASL findings could not be assessed. However, the study team's ability to recruit drug-naive ADHD patients was a great strength of the present study, allowing us to observe the rCBF alterations during a cognitive task regardless of the influence of ADHD treatment.

6. Conclusion

In sum, we found that children with ADHD displayed increased rCBF in the right anterior cingulate cortex (BA32) and frontopolar cortex (BA10 and 11) relative to control subjects during a cognitive attention task. Additionally, we observed increased rCBF in the dorsal and ventral network-associated parietal areas in these child ADHD patients relative to their counterparts. These results indicate that children with ADHD needed to over-activate their dorsal and ventral attention network-related regions to compensate for the attention demand by a given task.

Acknowledgement

The preliminary results of this study were presented as oral presentation in the 11th International Congress on Psychopharmacology & 7th International Symposium on Child and Adolescent Psychopharmacology (<https://www.tandfonline.com/doi/full/10.1080/24750573.2019.1608692>).

Disclosure statement

No potential conflict of interest was reported by the author(s).

Funding

The present research was financially supported by Ege University Scientific Research Council.

Notes on contributors

Burak Baytunca, MD completed his child and adolescent psychiatry residency training at Ege University in 2016. He is currently receiving his adult psychiatry training at University of Utah, Department of Psychiatry.

Blaise de B. Frederick, PhD, is an associate professor in psychiatry at Harvard Medical School and an associate biophysicist at McLean Hospital. He is also director of the Technical and Instrumentation Core at the McLean Imaging Center. He received a BS in physics from Yale University and a PhD in biophysics from the University of California at Berkeley.

Gul Unsel Bolat is MD at Child and Adolescent Psychiatry Department of Balikesir University and PhD candidate in Neuroscience at Ege University since 2018.

Burcu Kardaş is MD at Child and Adolescent Psychiatry Department of Gazi Yaşargil Education and Research Hospital.

Sevim Berrin İnci İzmir is MSc at Clinical Psychology Department of Işık University.

Melis İpçi is BS at Clinical Psychology Department of Hasan Kalyoncu University.

Cem Çallı is MD and Professor at Radiology Department of Ege University.

Onur Özyurt is PhD at Biomedical Engineering Department of Boğaziçi University.

Dost Öngür is William P. and Henry B. Test Professor of Psychiatry at Harvard Medical School, Chief of Center of Excellence in Psychotic Disorders and director of Schizophrenia and Bipolar Disorder Research Program at McLean Hospital. Dost also serves as the editor of JAMA Psychiatry.

Serkan Suren, MD completed his child&adolescent residency training at Ege University. He is now serving as assistant professor for Medical Park Hospital.

Eyüp Sabri Ercan is MD and Professor at Child and Adolescent Psychiatry Department of Ege University.

ORCID

Cem Callı  <http://orcid.org/0000-0001-9295-2866>

References

- [1] Rubia K. Cognitive neuroscience of Attention Deficit Hyperactivity Disorder (ADHD) and its clinical translation. *Front Hum Neurosci.* 2018;12:1–23. <http://journal.frontiersin.org/article/10.3389/fnhum.2018.00100/full>
- [2] Bench CJ, Frith CD, Grasby PM, et al. Investigations of the functional anatomy of attention using the stroop test. *Neuropsychologia.* 1993;31(9):907–922.
- [3] Coull JT, Frith CD, Frackowiak RSJ, et al. A fronto-parietal network for rapid visual information processing: a PET study of sustained attention and working memory. *Neuropsychologia.* 1996;34(11):1085–1095.
- [4] Lawrence NS, Ross TJ, Hoffmann R, et al. Multiple neuronal networks mediate sustained attention. *J Cogn Neurosci.* 2003;15(7):1028–1038.
- [5] Pardo JV, Fox PT, Raichle ME. Localization of a human system for sustained attention by positron emission tomography. *Nature.* 1991;349(6304):61–64.
- [6] Paus T, Zatorre RJ, Hofle N, et al. Time-related changes in neural systems underlying attention and arousal during the performance of an auditory vigilance task. *J Cogn Neurosci.* 1997;9(3):392–408.
- [7] Sturm W, De Simone, AK, Specht BJ, et al. Functional anatomy of intrinsic alertness: evidence for a fronto-parietal-thalamic-brainstem network in the right hemisphere. *Neuropsychologia.* 1999; 37(7):797–805.
- [8] Lee JS, Kim BN, Kang E, et al. Regional cerebral blood flow in children with attention deficit hyperactivity disorder: comparison before and after methylphenidate treatment. *Hum Brain Mapp.* 2005;24(3):157–164.
- [9] Kim J, Whyte J, Wang J, et al. Continuous ASL perfusion fMRI investigation of higher cognition: quantification of tonic CBF changes during sustained attention and working memory tasks. *Neuroimage.* 2006;31(1):376–385.
- [10] Kim BN, Lee JS, Cho SC, et al. Methylphenidate increased regional cerebral blood flow in subjects with attention deficit/hyperactivity disorder. *Yonsei Med J.* 2001;42(1):19–29.
- [11] Corbetta M, Patel G, Shulman GL. The reorienting system of the human brain: from environment to theory of mind. *Neuron.* 2008; 58(3):306–324.
- [12] Corbetta M, Kincade JM, Ollinger JM, et al. Voluntary orienting is dissociated from target detection in human posterior parietal cortex. *Nat Neurosci.* 2000;3(3):292–297.
- [13] Fox MD, Corbetta M, Snyder AZ, et al. Spontaneous neuronal activity distinguishes human. *Proc Natl Acad Sci.* 2006;103(25): 9381–9386.
- [14] Downar J, Crawley AP, Mikulis DJ, et al. The effect of task relevance on the cortical response to changes in visual and auditory stimuli: an event-related fMRI study. *Neuroimage.* 2001;14(6): 1256–1267.
- [15] Serences JT, Shomstein S, Leber AB, et al. Coordination of voluntary and stimulus-driven attentional control in human cortex. *Psychol Sci.* 2005;16(2):114–122.
- [16] Alsop DC, Detre JA. Multisection cerebral blood flow MR imaging with continuous arterial spin labeling. *Radiology.* 1998;208(2): 410–416. <http://pubs.rsna.org/doi/10.1148/radiology.208.2.9680569>
- [17] Aguirre GK, Detre JA, Zarahn E, et al. Experimental design and the relative sensitivity of BOLD and perfusion fMRI. *Neuroimage.* 2002;15(3):488–500.
- [18] Rao H, Wang J, Tang K, et al. Imaging brain activity during natural vision using CASL perfusion fMRI. *Hum Brain Mapp.* 2007; 28(7):593–601.
- [19] Liu T, Slotnick SD, Serences JT, et al. Cortical mechanisms of feature-based attentional control. *Cereb Cortex.* 2003;13(12): 1334–1343.
- [20] Mumford JA, Hernandez-Garcia L, Lee GR, et al. Estimation efficiency and statistical power in arterial spin labeling fMRI. *Neuroimage.* 2006;33(1):103–114.
- [21] Demeter E, Hernandez-Garcia L, Sarter M, et al. Challenges to attention: a continuous arterial spin labeling (ASL) study of the effects of distraction on sustained attention. *Neuroimage.* 2011; 54(2):1518–1529.
- [22] Lim J, Wu W, Chau Wang J, et al. Imaging brain fatigue from sustained mental workload: an ASL perfusion study of the time-on-task effect. *Neuroimage.* 2010;49(4):3426–3435.
- [23] Olson IR, Rao H, Moore KS, et al. Using perfusion fMRI to measure continuous changes in neural activity with learning. *Brain Cogn.* 2006;60(3):262–271.
- [24] O’Gorman RL, Mehta MA, Asherson P, et al. Increased cerebral perfusion in adult attention deficit hyperactivity disorder is normalised by stimulant treatment: a non-invasive MRI pilot study. *Neuroimage.* 2008;42(1):36–41.
- [25] McCarthy H, Skokauskas N, Frodl T. Identifying a consistent pattern of neural function in attention deficit hyperactivity disorder: a meta-analysis. *Psychol Med.* 2014;44(4):869–880.
- [26] APA. American Psychiatric Association. Diagnostic and statistical manual of mental disorders. (5th ed.). American Journal of Psychiatry; Istanbul, Turkey: Galenos Yayınevi, 2013.
- [27] Ercan ES, Amado SS. Development of a test battery for the assessment of attention deficit hyperactivity disorder. *Çocuk ve Gençlik Ruh Sağlığı Derg/Turkish. J Child Adolesc Ment Heal.* 2001;8(3):132–144. <http://www.scopemed.org/?mno=34211>
- [28] Achenbach TM. Integrative Guide ot the 1991 CBCL/4-18 YSR, and TRF Profiles. Univ Vermont, Dep Psychol Pediatr. 1991.
- [29] Ercan ES, Suren S, Bacanlı A, et al. Decreasing ADHD phenotypic heterogeneity: searching for neurobiological underpinnings of the restrictive inattentive phenotype. *Eur Child Adolesc Psychiatr.* 2016;25(3):273–282.
- [30] Jenkinson M, Bannister P, Brady M, et al. Improved optimization for the robust and accurate linear registration and motion correction of brain images. *Neuroimage.* 2002;17(2):825–841.
- [31] Lancaster JL, Woldorff MG, Parsons LM, et al. Automated Talairach Atlas labels for functional brain mapping. *Hum Brain Mapp.* 2000;10(3):120–131.
- [32] Bush G. Cingulate, frontal, and parietal cortical dysfunction in attention-deficit/hyperactivity disorder. *Biol Psychiatry.* 2011; 69(12):1160–1167.

- [33] Peterson BS, Kane MJ, Alexander GM, et al. An event-related functional MRI study comparing interference effects in the Simon and Stroop tasks. *Cogn Brain Res*. 2002;13(3):427–440.
- [34] Fan J, Flombaum JI, McCandliss BD, et al. Cognitive and brain consequences of conflict. *Neuroimage*. 2003;18(1):42–57.
- [35] Dickstein SG, Bannon K, Xavier Castellanos F, et al. The neural correlates of attention deficit hyperactivity disorder: an ALE meta-analysis. *J Child Psychol & Psychiat*. 2006;47(10):1051–1062.
- [36] Hart H, Radua J, Nakao T, et al. Meta-analysis of functional magnetic resonance imaging studies of inhibition and attention in attention-deficit/hyperactivity disorder: exploring task-specific, stimulant medication, and age effects. *JAMA Psychiatry*. 2013;70(2):185–198.
- [37] Norman LJ, Carlisi C, Lukito S, et al. Structural and functional brain abnormalities in attention-deficit/hyperactivity disorder and obsessive-compulsive disorder: a comparative meta-analysis. *JAMA Psychiatry*. 2016;73(8):815–825.
- [38] Castellanos FX, Margulies DS, Kelly C, et al. Cingulate-precuneus interactions: a new locus of dysfunction in adult attention-deficit/hyperactivity disorder. *Biol Psychiatry*. 2008;63(3):332–337.
- [39] Buckner RL, Andrews-Hanna JR, Schacter DL. The brain's default network: anatomy, function, and relevance to disease. *Ann N Y Acad Sci*. 2008;1124:1–38.
- [40] Raichle ME. The brain's default mode network. *Annu Rev Neurosci*. 2015;38(1):433–447.
- [41] Schulz KP, Fan J, Tang CY, et al. Response inhibition in adolescents diagnosed with attention deficit hyperactivity disorder during childhood: an event-related fMRI study. *Am J Psychiatry*. 2004;161(9):1650–1657.
- [42] Durston S, Tottenham NT, Thomas KM, et al. Differential patterns of striatal activation in young children with and without ADHD. *Biol Psychiatry*. 2003;53(10):871–878.
- [43] Schweitzer JB, Faber TL, Grafton ST, et al. Alterations in the functional anatomy of working memory in adult attention deficit hyperactivity disorder. *Am J Psychiatry*. 2000;157(2):278–280.
- [44] Gondo Y, Shimonaka Y, Senda M, et al. The role of the prefrontal cortex in the go/no-go task in humans: a positron emission tomography study. *Jpn Psychol Res*. 2000;42(1):36–44.
- [45] Simmonds DJ, Pekar JJ, Mostofsky SH. Meta-analysis of go/no-go tasks demonstrating that fMRI activation associated with response inhibition is task-dependent. *Neuropsychologia*. 2008;46(1):224–232.
- [46] Bludau S, Eickhoff SB, Mohlberg H, et al. Cytoarchitecture, probability maps and functions of the human frontal pole. *Neuroimage*. 2014;93:260–275. <http://dx.doi.org/10.1016/j.neuroimage.2013.05.052>
- [47] Gilbert SJ, Spengler S, Simons JS, Steele JD, et al. Functional specialization within rostral prefrontal cortex (area 10): a meta-analysis. *J Cogn Neurosci*. 2006;18(6):932–948.
- [48] Niendam TA, Laird AR, Ray KL, et al. Meta-analytic evidence for a superordinate cognitive control network subserving diverse executive functions. *Cogn Affect Behav Neurosci*. 2012;12(2):241–268.
- [49] Chahine G, Diekhof EK, Tinnermann A, et al. On the role of the anterior prefrontal cortex in cognitive “branching”: an fMRI study. *Neuropsychologia*. 2015;77:421–429.
- [50] Willcutt EG, Doyle AE, Nigg JT, et al. Validity of the executive function theory of attention-deficit/hyperactivity disorder: a meta-analytic review. *Biol Psychiatry*. 2005;57(11):1336–1346.
- [51] Winstanley CA, Eagle DM, Robbins TW. Behavioral models of impulsivity in relation to ADHD: translation between clinical and preclinical studies. *Clin Psychol Rev*. 2006;26(4):379–395.
- [52] Barkley RA. Behavioral inhibition, sustained attention, and executive functions: constructing a unifying theory of ADHD. *Psychol Bull*. 1997;121(1):65–94.
- [53] Nigg JT. Response inhibition and disruptive behaviors: toward a multiprocess conception of etiological heterogeneity for adhd combined type and conduct disorder early-onset type. *Ann NY Acad Sci*. 2003;1008(1):170–182.
- [54] Sergeant JA, Geurts H, Oosterlaan J. How specific is a deficit of executive functioning for attention-deficit/hyperactivity disorder? *Behav Brain Res*. 2002;130(1–2):3–28.
- [55] Berlin HA, Rolls ET, Kischka U. Impulsivity, time perception, emotion and reinforcement sensitivity in patients with orbitofrontal cortex lesions. *Brain*. 2004;127(5):1108–1126.
- [56] Winstanley CA, Theobald DEH, Cardinal RN, et al. Contrasting roles of basolateral amygdala and orbitofrontal cortex in impulsive choice. *J Neurosci*. 2004;24(20):4718–4722.
- [57] Bechara A, Van Der Linden M. Decision-making and impulse control after frontal lobe injuries. *Current Opinion in Neurology*. 2005;18(6):734–739.
- [58] Kringelbach ML, Rolls ET. The functional neuroanatomy of the human orbitofrontal cortex: evidence from neuroimaging and neuropsychology. *Prog Neurobiol*. 2004;72(5):341–372.
- [59] Cubillo A, Halari R, Smith A, et al. A review of fronto-striatal and fronto-cortical brain abnormalities in children and adults with Attention Deficit Hyperactivity Disorder (ADHD) and new evidence for dysfunction in adults with ADHD during motivation and attention. *Cortex*. 2012;48(2):194–215. <http://dx.doi.org/10.1016/j.cortex.2011.04.007>
- [60] Tegelbeckers J, Kanowski M, Krauel K, et al. Orbitofrontal signaling of future reward is associated with hyperactivity in attention-deficit/hyperactivity disorder. *J Neurosci*. 2018;38(30):6779–6786.
- [61] Eklund A, Nichols TE, Knutsson H. Cluster failure: why fMRI inferences for spatial extent have inflated false-positive rates. *Proc Natl Acad Sci USA*. 2016;113(28):7900–7905. <http://www.pnas.org/lookup/doi/10.1073/pnas.1602413113>
- [62] Spreng RN, Sepulcre J, Turner GR, et al. Intrinsic architecture underlying the relations among the default, dorsal attention, and frontoparietal control networks of the human brain. *J Cogn Neurosci*. 2015;25(1):74–86.
- [63] Margulies DS, Vincent JL, Kelly C, et al. Precuneus shares intrinsic functional architecture in humans and monkeys. *Proc Natl Acad Sci USA*. 2009;106(47):20069–20074. <http://www.pnas.org/cgi/doi/10.1073/pnas.0905314106>
- [64] Cavanna AE, Trimble MR. The precuneus: a review of its functional anatomy and behavioural correlates. *Brain*. 2006;129(Pt 3):564–583.
- [65] Hedden T, Gabrieli JDE. Shared and selective neural correlates of inhibition, facilitation, and shifting processes during executive control. *Neuroimage*. 2010;51(1):421–431.
- [66] Krall SC, Rottschy C, Oberwelland E, et al. The role of the right temporoparietal junction in attention and social interaction as revealed by ALE meta-analysis. *Brain Struct Funct*. 2015;220(2):587–604.
- [67] Shomstein S, Yantis S. Control of attention shifts between vision and audition in human cortex. *J Neurosci*. 2004;24(47):10702–10706. <http://www.jneurosci.org/cgi/doi/10.1523/JNEUROSCI.2939-04.2004>
- [68] Tosoni A, Shulman GL, Pope ALW, et al. Distinct representations for shifts of spatial attention and changes of reward contingencies in the human brain. *Cortex*. 2013;49(6):1733–1749. <http://dx.doi.org/10.1016/j.cortex.2012.03.022>
- [69] Shulman GL, Astafiev SV, Franke D, et al. Interaction of Stimulus-driven reorienting and expectation in ventral and dorsal frontoparietal and basal Ganglia-cortical networks. *J Neurosci*. 2009;29(14):4392–4407.
- [70] Christakou A, Murphy CM, Chantiluke K, et al. Disorder-specific functional abnormalities during sustained attention in youth with Attention Deficit Hyperactivity Disorder (ADHD) and with Autism. *Mol Psychiatry*. 2013;18(2):236–244. <http://dx.doi.org/10.1038/mp.2011.185>
- [71] Rubia K, Smith AB, Halari R, et al. Disorder-specific dissociation of orbitofrontal dysfunction in boys with pure conduct disorder during reward and ventrolateral prefrontal dysfunction in boys with pure ADHD during sustained attention. *Am J Psychiatry*. 2009;166(1):83–94.

- [72] Hart H, Radua J, Mataix-Cols D, et al. Neuroscience and biobehavioral reviews meta-analysis of fMRI studies of timing in attention-deficit hyperactivity disorder (ADHD). *Neurosci Biobehav Rev.* 2012;36(10): 2248–2256. <http://dx.doi.org/10.1016/j.neubiorev.2012.08.003>
- [73] Wang S, Yang Y, Xing W, et al. Altered neural circuits related to sustained attention and executive control in children with ADHD: an event-related fMRI study. *Clin Neurophysiol.* 2013; 124(11):2181–2190. <http://dx.doi.org/10.1016/j.clinph.2013.05.008>